

Case Report

Occult oncocyoma of the lacrimal sac

Kaustubh Mulay, DNB^{a,b,*}; Akshay Nair, DNB^c; Santosh G. Honavar, MS, FACS^{c,d}

Abstract

Oncocyoma of the lacrimal sac is a rarely encountered clinical entity. We report the case of a 72-year-old female patient who was diagnosed to have bilateral nasolacrimal duct obstruction during a pre-cataract surgery screening. Subsequently, she underwent bilateral dacryocystectomy. Histopathological examination of the left lacrimal sac revealed a tumour composed of acini lined by oncocyctic cells; features consistent with those of a lacrimal sac oncocyoma. Although rare, oncocytomas arising from the lacrimal sac may co-exist with a nasolacrimal duct obstruction. This report describes the histological and immunochemistry characteristics of oncocytomas and underscores the need to subject all excised lacrimal sacs to histopathological examination.

Keywords: Lacrimal sac, Oncocyoma, Occult

© 2013 Production and hosting by Elsevier B.V. All rights reserved.
<http://dx.doi.org/10.1016/j.sjopt.2013.08.003>

Introduction

Acquired nasolacrimal duct obstruction (NLDO) is caused by chronic inflammation. Rarely, lacrimal sac tumours are a cause of NLDO.¹ Oncocytomas of the lacrimal sac are rare with very few cases documented in the recent literature.^{2–6} We report an oncocyoma of the lacrimal sac presenting as an asymptomatic NLDO diagnosed as an incidental finding in a 72-year-old female.

Case history

A 72-year-old systemically healthy female presented to our clinic with complaints of progressive painless diminution of vision in both eyes. Visual acuity was found to be finger counting at 2 m in both eyes. The ocular adnexae were normal and slit lamp examination revealed a grade III nuclear sclerosis in both eyes with posterior subcapsular cataract. Intraocular pressure and fundus were normal. She was ad-

vised cataract surgery with intraocular lens implantation sequentially in both eyes. During pre-operative evaluation, she was found to have nasolacrimal duct obstruction on both sides. In view of her advanced cataract, poor vision and old age, she underwent bilateral dacryocystectomy, prior to cataract surgery. The surgery was performed under local anaesthesia with a curvilinear incision made over the anterior lacrimal crest. The lacrimal sacs were completely excised. The excised lacrimal sacs were found to be unremarkable in size, texture and consistency. Histopathological examination of the left lacrimal sac revealed a circumscribed nodular, submucosal tumour composed of acini (Fig. 1A) lined by oncocyctic cells having abundant, granular and eosinophilic cytoplasm and vesicular nuclei (Fig. 1B and C). Mitotic activity or vascular invasion was not seen. Immunohistochemical staining revealed immunoreactivity for pan-cytokeratin (CK), CK7 and CK19 (Fig. 2A–C). The tumour cells were negative for CK20. The right lacrimal sac displayed chronic inflammation and fibrosis.

Received 30 July 2013; received in revised form 19 August 2013; accepted 27 August 2013; available online xxxx.

^a National Reporting Centre for Ophthalmic Pathology, Centre for Sight, Hyderabad 500034, India

^b Ocular Pathology Service, L.V. Prasad Eye Institute, Hyderabad, India

^c Department of Oculoplastics and Ocular Oncology, L.V. Prasad Eye Institute, Hyderabad, India

^d Oculoplastics and Ocular Oncology, Centre for Sight, Hyderabad, India

* Corresponding author at: National Reporting Centre for Ophthalmic Pathology, Centre for Sight, Ashoka Capitol Building, Banjara Hills, Road No. 2, Hyderabad 500034, India. Tel.: +91 9030933453.

e-mail address: kaustubh.m@hotmail.com (K. Mulay).



Peer review under responsibility
of Saudi Ophthalmological Society,
King Saud University



Production and hosting by Elsevier

Access this article online:
www.saudiophthaljournal.com
www.sciencedirect.com

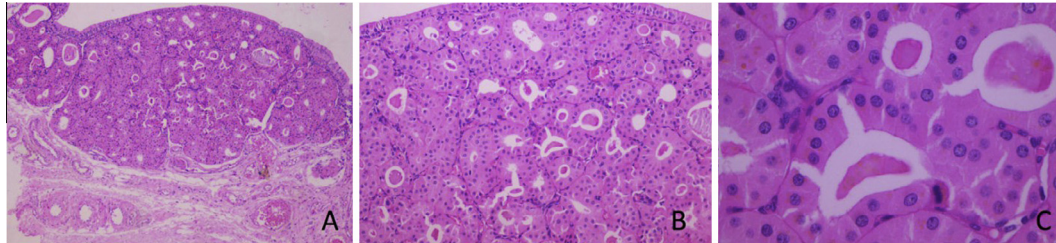


Figure 1. (A) Circumscribed, submucosal nodule with an intact overlying lacrimal sac epithelium (H and E, $\times 20$). (B) Tumour cells in an acinar pattern with central lumina and intervening, delicate vascular septae (H and E, $\times 100$). (C) Oncocytic cells with abundant, granular, eosinophilic cytoplasm and uniform, vesicular nuclei (H and E, $\times 400$).

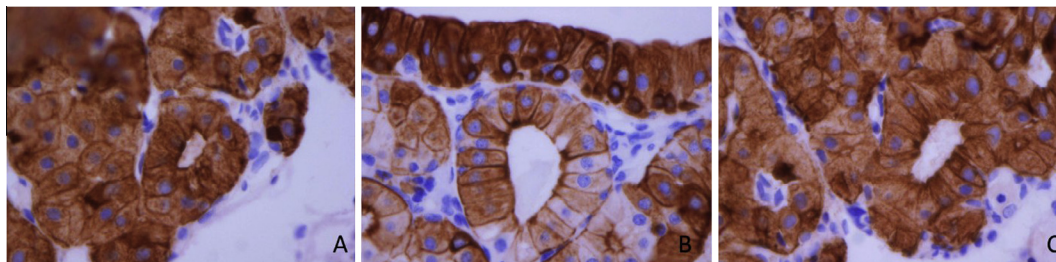


Figure 2. (A) Immunoreactivity for pan-cytokeratin [CK] ($\times 400$). (B) Immunoreactivity for CK7 [CK7] ($\times 400$). (C) Immunoreactivity for CK19 [CK19] ($\times 400$).

Discussion

Primary nasolacrimal duct obstruction (NLDO) usually presents with symptomatic epiphora. In our case, NLDO was asymptomatic and diagnosed during routine pre-operative evaluation for cataract surgery. Chronic inflammation and fibrosis can cause NLDO. However, NLDO may be occasionally caused by lacrimal sac tumours, trauma, irradiation, dacryoliths or sarcoidosis.⁷ Tumours of the lacrimal sac are rare, majority of these being epithelial in nature.⁸ Oncocytomas of the lacrimal sac are even more rare.³⁻⁶

The term 'oncocyte' was first used by Hamperl to describe transformation of an aged, 'functionally overtaxed' epithelial cell into a swollen degenerated cell.⁹ Oncocytic lesions of the lacrimal sac include metaplasia, hyperplasia and oncocytoma. A similar cytokeratin (CK) expression pattern in these lesions suggests that these represent the similar lesions in different stages of development.² Histological differentiation between metaplasia/hyperplasia and hyperplasia/adenoma is not always clear.¹⁰ The oncocytic epithelium expresses CK7, CK8, CK18 and CK 19 strongly. A positive reaction for CK4, CK5/6, CK13 and CK14 has also been reported.² In our case, the oncocytes expressed pan-cytokeratin, CK7 and CK 19. CK20 was negative in these cells as has been described in the literature.² Abundance of mitochondria accounts for the granular nature of oncocytes as has been demonstrated by a positive reactive to phosphotungstic acid and haematoxylin (PTAH) stain and immunoreactivity for anti-mitochondrial antibodies.^{2,11} This has further been confirmed by electron microscopic examination of these cells' demonstration of numerous normal and abnormal mitochondria. Thus, oncocytoma has been sometimes referred to as a mitochondrioma.^{2,9} Benign oncocytomas can recur or transform to a

malignant oncocytoma.¹² Hence a complete surgical resection is the treatment of choice with a long term follow-up for local recurrence.^{13,14}

To conclude, it is important that clinicians should be aware that lacrimal sac tumours such as oncocytoma may be occult, though rare. It would be ideal to subject all excised lacrimal sacs to histopathological examination.

Conflict of interest

The authors declare that there is no conflict of interest.

References

1. Pe'er J, Hidayat AA, Ilsar M, Landau L, Stefanyzyn MA. Glandular tumours of the lacrimal sac. *Ophthalmol* 1996;**103**: 1601–5.
2. Østergaard J, Prause JU, Heegaard S. Oncocytic lesions of the ophthalmic region: a clinicopathological study with emphasis on cytokeratin expression. *Acta Ophthalmol* 2011;**89**:263–7.
3. Domanski H, Ljunberg O, Anderson LO, Schele B. Oxyphil cell adenoma (oncocytoma) of the lacrimal sac review of the literature. *Acta Ophthalmol* 1994;**72**:393–6.
4. O'Connor SR, Tan JH-Y, Walewska R, Brown LJR, Lauder I. Angiotropic lymphoma in a lacrimal sac oncocytoma. *J Clin Pathol* 2002;**55**:787–8.
5. Bigg SL, Font RL. Oncocytic lesions of the caruncle and other ocular adnexae. *Arch Ophthalmol* 1977;**95**:474–8.
6. Picorella I, Garner A. Ostensible oncocytoma of the minor salivary glands. *Histopathology* 1997;**30**:264–70.
7. Anderson NG, Wojno TH, Grossniklaus HE. Clinicopathologic findings from lacrimal sac biopsy specimens obtained during dacryocystorhinostomy. *Ophthalm Plast Reconstr Surg* 2003;**19**: 173–6.
8. Stefanyzyn M, Hidayat A, Pe'er J, Flanagan J. Lacrimal sac tumours. *Ophthalm Plast Reconstr Surg* 1994;**118**:650–8.
9. Hamperl H. Benign and malignant oncocytomas. *Cancer* 1962;**15**:1019–27.

10. Ellis GL, Auclair PL. Tumors of the salivary glands *Atlas of tumor pathology, 3rd series, fascicle 17*. Washington, DC: Armed Forces Institute of Pathology; 1996. p. 318–24.
11. Marglam O, Alherabi A, Corsten M. Malignant oncocytoma of the lacrimal sac with cervical metastasis: case report and literature review. *J Otolaryngol Head Neck Surg* 2008;**37**:e8–e10.
12. Heathcote JG, Kumalo TG, Willis NR, Mills DM. Oncocytoma of the lacrimal caruncle. *Can J Ophthalmol* 1986;**21**:178–83.
13. Kamamoto K, Nakahara K, Takeuchi H. Malignant oncocytoma of the parotid gland: report of a case and review of the literature. *Yonago Acta Med* 2001;**44**:125–30.
14. Perlman JI, Specht CS, Maclean IW, Wolfe SA. Department of Ophthalmic Pathology, Armed Forces Institute of Pathology, Washington DC, USA. Oncocytic adenocarcinoma of lacrimal sac: report of a case with paranasal sinus and orbital extension. *Ophthalmic Surg* 1995;**26**(4):377–9.